

I, Kevin Plowright of the Royal Society for the Prevention of Cruelty to Animals (Auckland) have good cause to suspect

**Charge 29**

Failing to meet physical, health and behavioural needs of animal  
Animal Welfare Act 1999  
Section 10, 12(a) and 25

**CRN: 18092503986**

That JANINE ANNE WALLACE, between 28 July 2017 & 13 October 2017, at Mangatawhiri, being a person in charge of an animal, namely a German Shepherd dog named Ritza, did not ensure that the physical, health and behavioural needs of that animal were met in a manner that was in accordance with good practice.

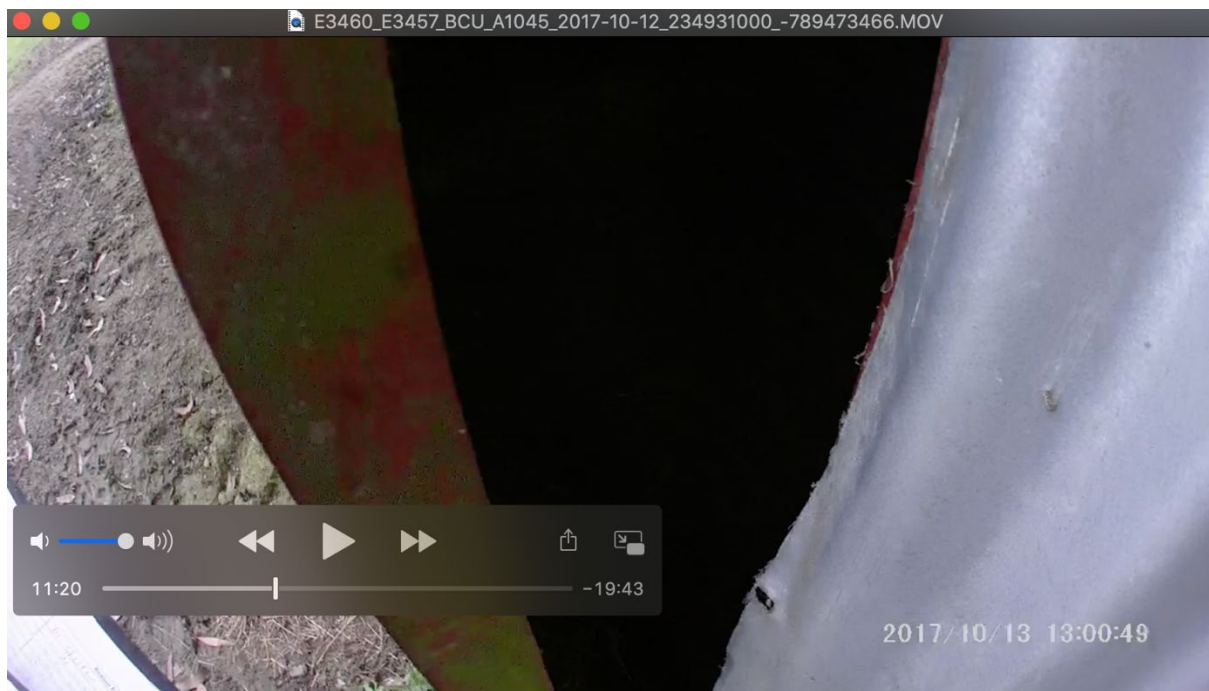Particulars:

Unsatisfactory tethering (lead twisted around leg);  
No access to water;  
Unhygienic conditions (faecal build-up);  
No behavioural enrichment.

**Charges 29 and 65: Ritza on 13 October 2017 Pages 82-84 [351 – 357]**

**HAYBARN on 13.10.2017 at 1 pm**

L Davis walks over to Hay Barn doors and looks inside.  
K Plowright said: "what's in there?"  
L Davis said: "Dogs" "Kev there are dogs in here."  
K Plowright said: "Crated? Loose?"  
L Davis said: "Chained"

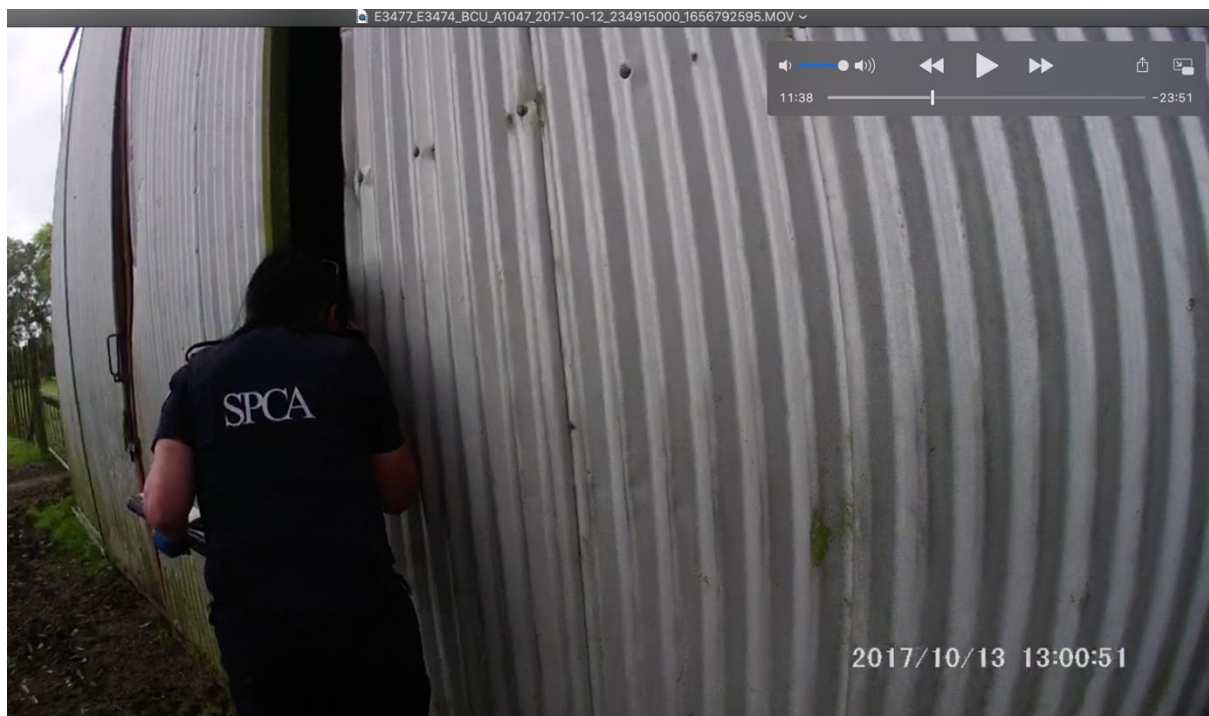


**13:00:49 Body Worn Camera 13.10.2017 L Davis** – walking towards the opening of the Hay Barn to take a look inside.



**13:00:50 Body Worn Camera K Plowright 13.10.2017** as L Davis looks inside the Hay Barn

**13:00:51 Body Worn Camera Footage 13.10.2017 K Plowright** E3477\_E3474\_BCU\_A1047\_2017-10-12\_234915000\_1656792595.MOV



**13:00:52-59 Body Worn Camera K Plowright, Plowright walks over looks inside the haybarn sees the dogs and Rhys Heatley**




**13:00:49 – 58 Body Worn Camera Footage K Plowright of L**



Davis looking inside the Hay Barn, she then moves away to enable K Plowright to have a look himself.

**13:00:57 Body Worn Camera L Davis AUDIO Rhys Heatley** inside the Hay Barn, Rhys entered through the back of hay barn's identical double doors. He closes the double doors behind him! Rhys said: **"What are you doing in here?"**  
**WHO IS RHYS TALKING TO???**








**13:00:59 Body Worn Camera K Plowright** right hand about to look into the Hay Barn



**13:01:01 Body Worn Camera K Plowright – Rhys Heatley** inside Haybarn walking with Ritza 1 of 2 screen shots



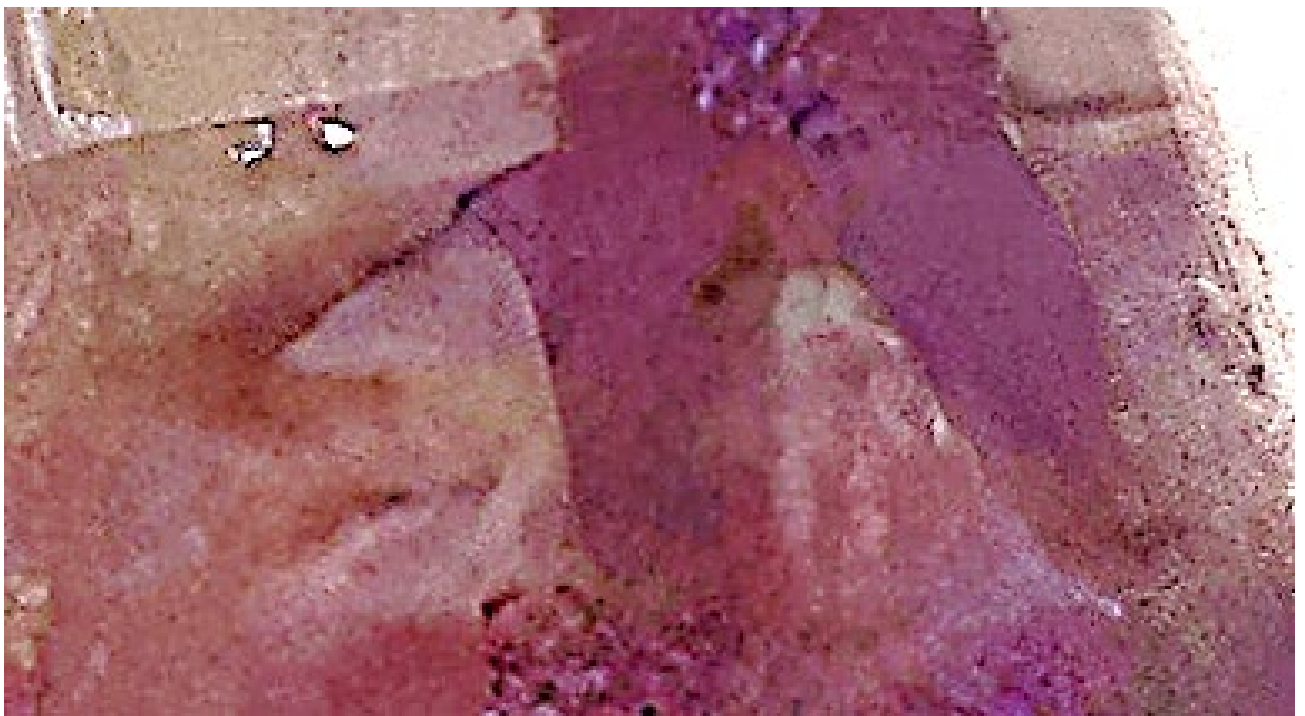
**13:01:02 Body Worn Camera K Plowright – Rhys Heatley**  
inside Haybarn with Ritza 2 of 2 screen shots



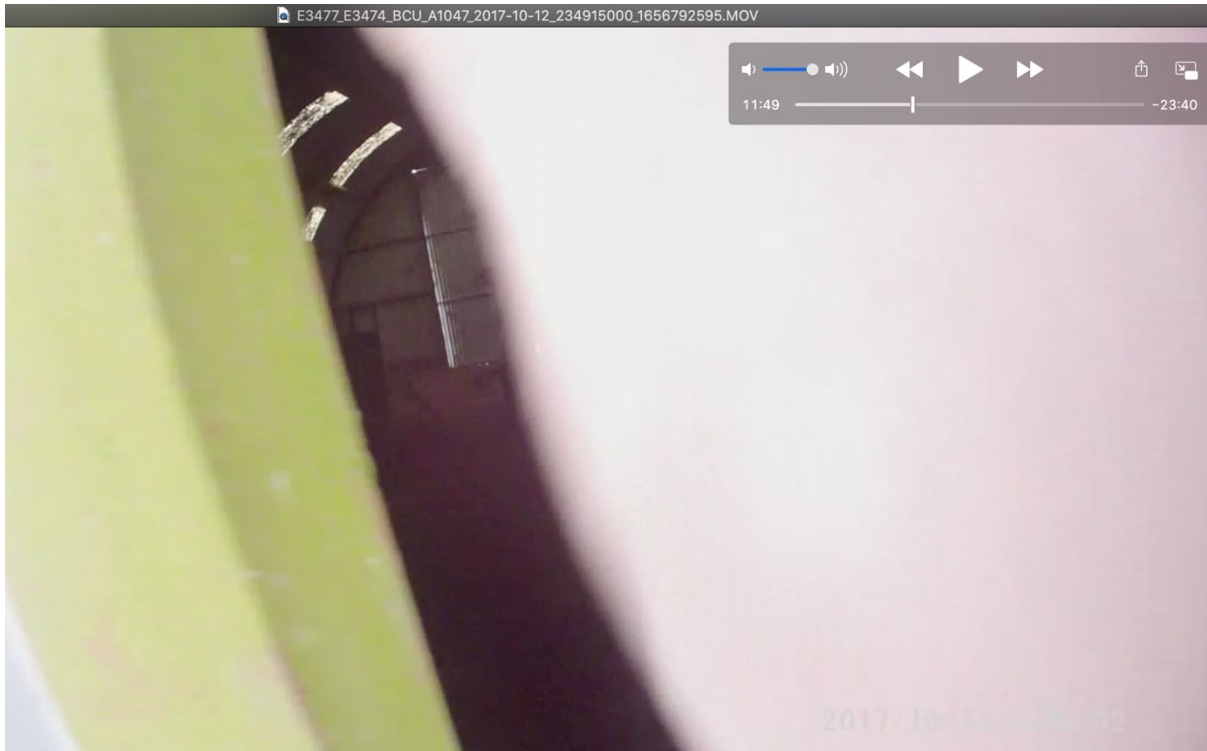Enhanced Image showing a dog outside the cage



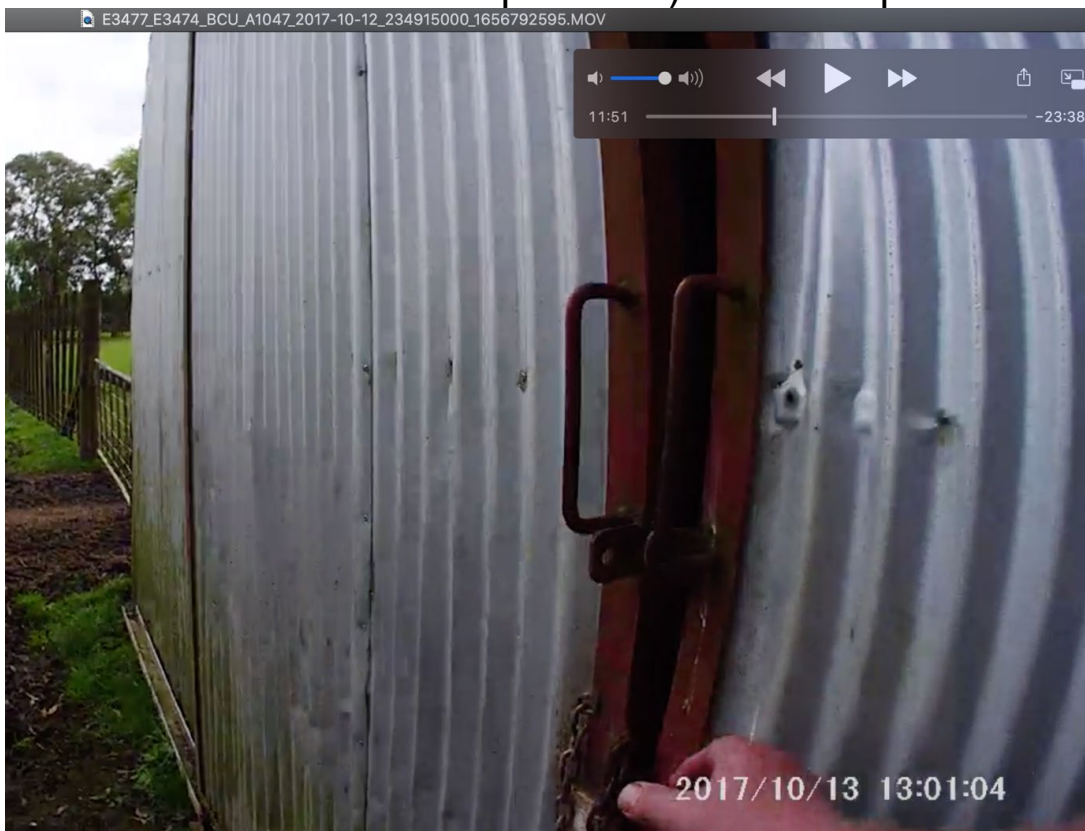Note Dog next to his leg







**13:01:02 Body Worn Camera K Plowright** putting his arm in front of the camera 1 of 2 images (K Plowright does this on numerous occasions of importance) to cover up



**13:01:04 Body Worn Camera K Plowright** reaches out to the pin on the chain holding both sliding haybarn doors together

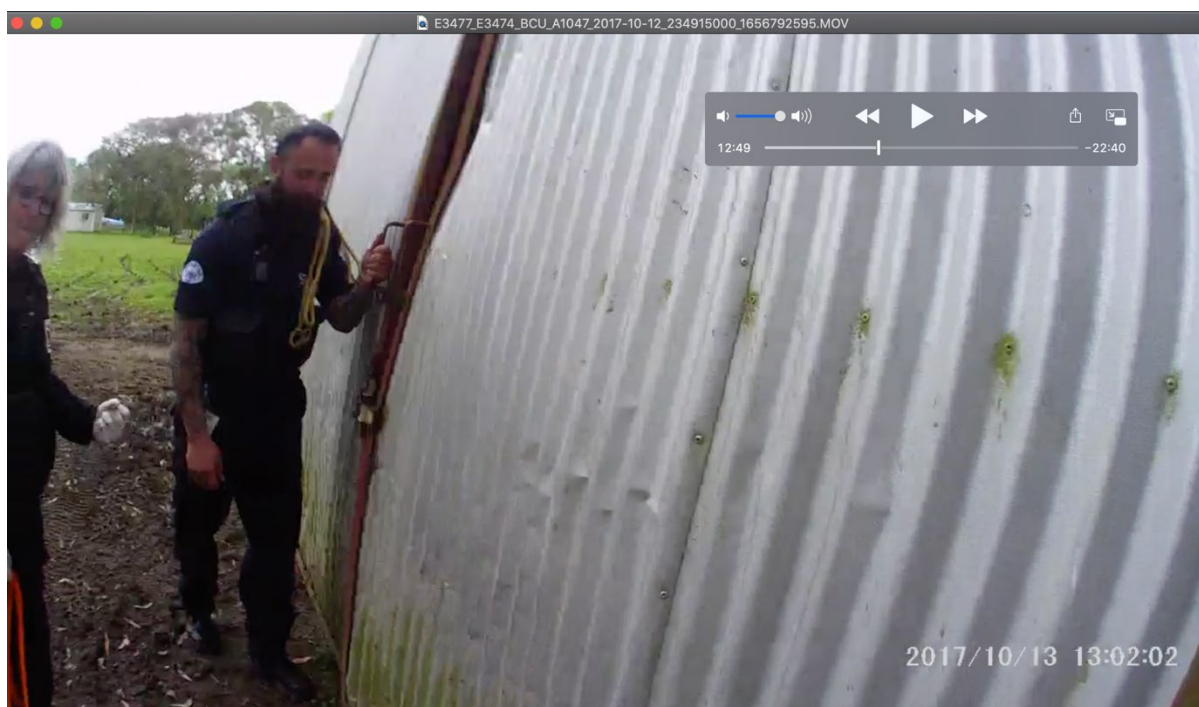


**13:01:06 Body Worn Camera K Plowright** standing in front of the double haybarn doors looking inside the haybarn.



**13:01:20 – 13:01:25 Body Worn Camera L Davis** Dr Beer standing at the front of Dani's area states: **"Conformity if you take one with an ear infection you probably should take them both."** (Referring to Dani). J Beer confirms **ONLY 2** with probable ear infections at 13:01:20 on 13.10.2017.





**13:02:02 Body Worn Camera K Plowright** Joanna Smout  
Waikato District Council & SPCA Inspector Andre Williams at  
Haybarn front double doors

IMPORTANT TO NOTE PLOWRIGHT & DAVIS CONFIRM  
THEY BOTH SAW RHYS HEATLEY INSIDE THE HAYBARN  
WALKING TOWARDS THE CRATE **2 MINUTES BEFORE**.  
THESE EXACT TIMES ARE DOCUMENTED ON EACH  
PHOTO FROM Body Worn Camera footages.

**PLOWRIGHT CREATES A COMMOTION 2 MINUTES AFTER  
SEEING RHYS HEATLEY INSIDE HAYBARN WITH RITZA.**

[347] Judge Grau "I simply note here - I do not accept there was a high level of  
"commotion" involved in the entry to the barn that Ms Wallace alleged.

**Evidence** from Body Worn Camera Footage 13 October 2017 L Davis @13:02:04 -  
13:02:33 E3460\_E3457\_BCU\_A1045\_2017-10-12\_234931000\_-  
789473466.MOV **confirming with commotion with Mr K Plowright picking up a  
large Builder's concrete block and smashing it 10 times against the Hay Barn  
door.** A total of at least 10 People present at the Hay Barn namely K Plowright; L  
Davis; J Beer; Rhys Heatley; Jo from Waikato District Council; Katie Wright SPCA;  
Todd Kircher Tuakau Police; Lloyd SPCA Inspector; Robert SPCA Inspector; and



SPCA Inspector Andre causing a big commotion. Including one SPCA vehicle directly parked at the Hay Barn other vehicles were closeby.



**13:02:00 Body Worn Camera K Plowright**

K Plowright said "It's alright, I have got the key"

Picks up the builder's concrete block at the end of the Haybarn, walks to the double doors and smashed the concrete block 10x against the doors.





13:02:15 – 22 Body Worn Camera L Davis Photo and AUDIO says

L. Davis: “Kev, Rhys is already in there! “

K Plowright: “Yeah but can he get the dogs out without clambering over a whole lot of shit to get out?”

L Davis walks over and looks through the doors and says: “Yeah”





**13:02:26 Body Worn Camera K Plowright**

Fenton SPCA inspector says "I have a hammer and crowbar"

K Plowright "Oh have you?"

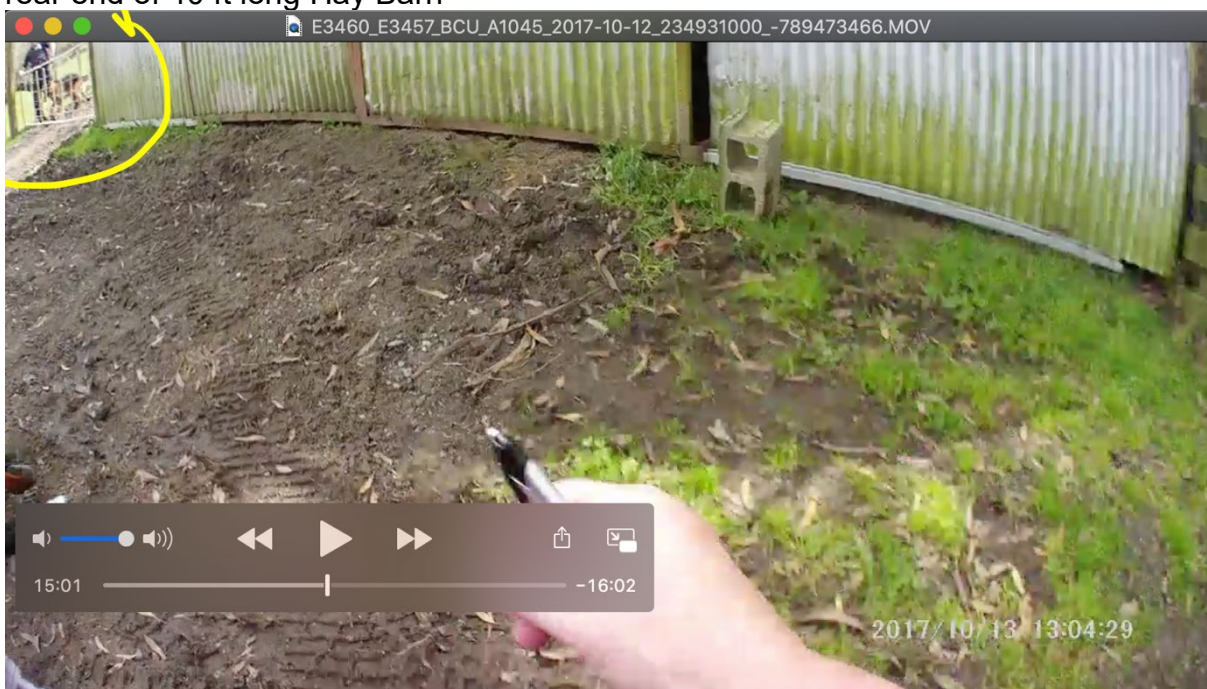
Fenton "Yeah"

**13:02:40 Body Worn Camera K Plowright** "Well if you don't mind doing that Fenton, I want to go and take some photos under the Wool Shed." And walks to the Wool Shed



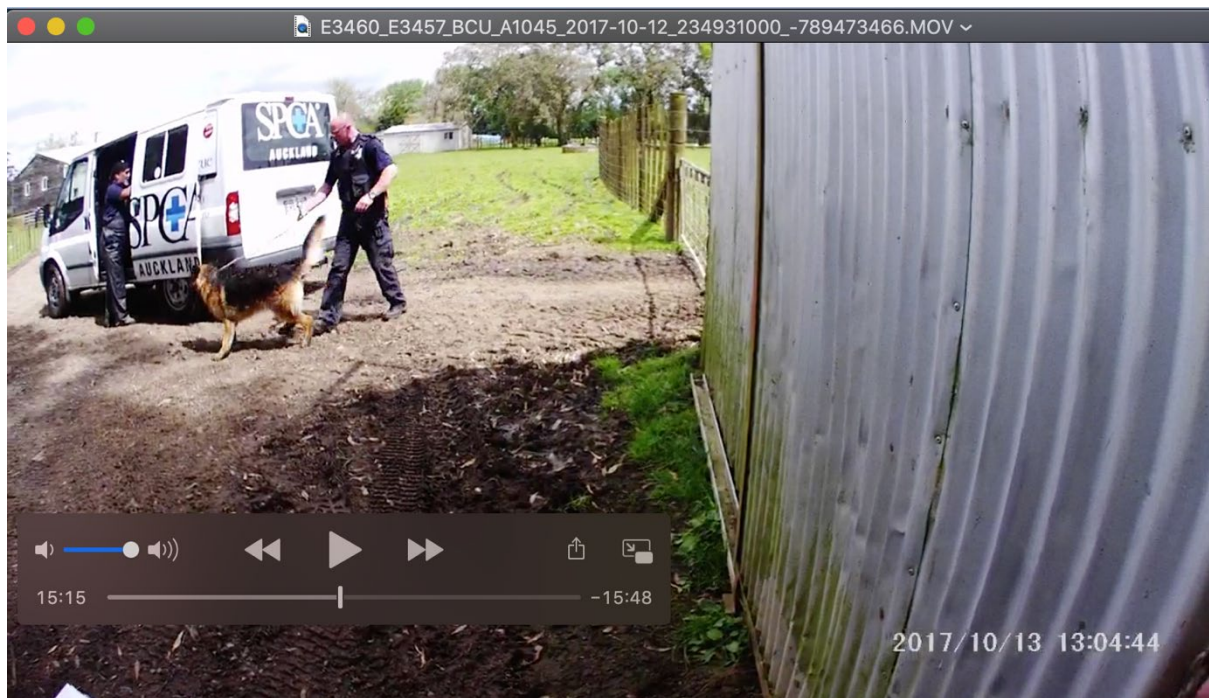


**13:03:46-54 Body Worn Camera L Davis - Rhys Heatley putting a lead on Dani at rear end of 40 ft long Hay Barn**

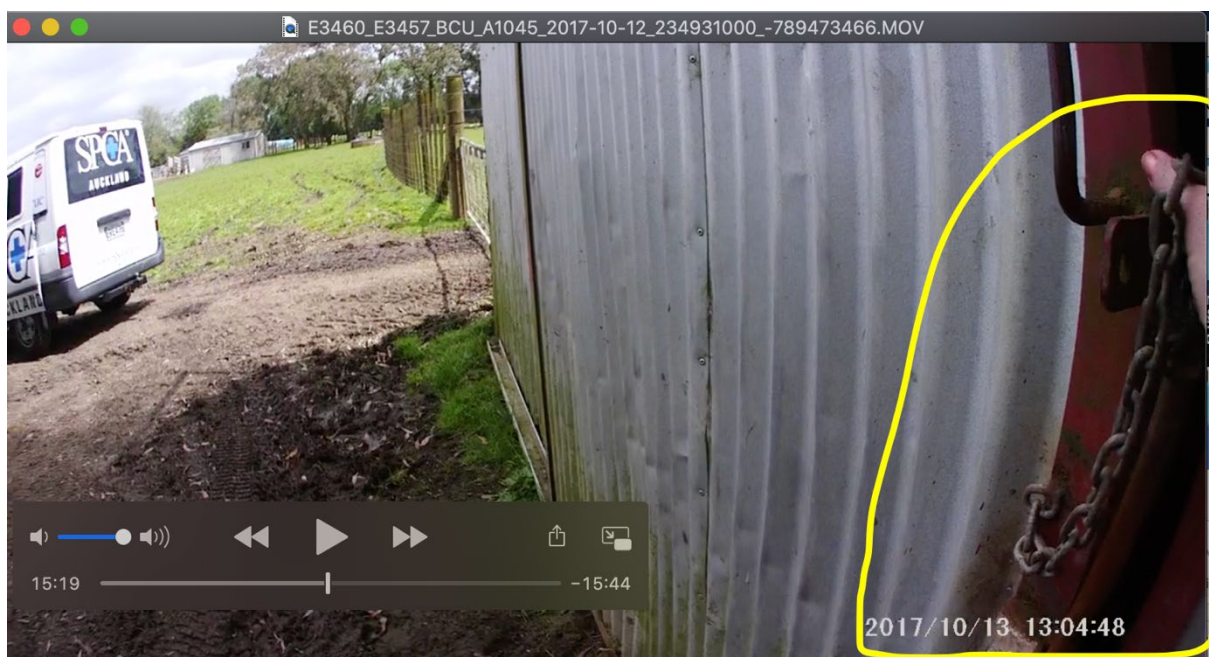

**13:04:29 Body worn Camera L Davis - Rhys Heatley is at the front end of the Haybarn gate with Dani**





**13:04:44 Body Worn Camera L Davis - Rhys Heatley walking Dani to Fenton's SPCA vehicle in front of Haybarn and putting Dani into Fenton's vehicle**




**13:04:48 Body Worn Camera L Davis 13.10.2017 opening the bolt, releasing the double hay barn doors to enter from the front.**

**13:04:59 Body Worn Camera L Davis 13 Oct 2017 AUDIO**

L Davis "Is there only one in here Rhys?"

R Heatley "No, two"

L Davis slides open the double Haybarn doors and enters with Dr Beer.



**13:05:08 - 13:00: Body Worn Camera L Davis Entering the Haybarn through front double doors with Dr Beer. NB The rear end double Hay Barn Doors are NOW open.**

**13:05:29** Dr Beer walks towards Ritza looks and returns to Pirelli.

**13:05: 33 – 13:05:42** Another SPCA Inspector Andre Williams walks to Ritza and stands in front of her. Ritza lies there wagging her tail.

**13:06:17 Body Worn Camera L Davis AUDIO** Dr Beer says “He should go”

**13:07:09 Body Worn Camera L Davis AUDIO** Dr Beer says “This one is tied up, you want to get a photo of it, the leg is by her head.”

**Seven Minutes after Rhys Heatley is filmed on K Plowright’s Body Worn Camera footage inside the Haybarn.**



Photo taken by Lauri Davis after the Inspectors have stood and watched her for several minutes



**13:07:30 K Plowright's Body Camera Footage** stops in front of the Hay Barn after walking to the Wool shed to take photos and remains like that for 16 minutes and 34 seconds.

[351] Judge Grau "Ritza received medical treatment after she was taken into SPCA custody, but it was unsuccessful, the leg worsened, and she had to be euthanised."

Transcript Manukau District Court January 2022 Page 353 of 1,098 Lines 19 -26  
Dr Beer's Evidence in Chief

- 20 Q. So take your time to find the right place if you need to because there's quite a bit in relation to **Ritzer**.
- A. Yes.
- Q. And then tell us what happened subsequent to her being found there and examined on site, what happened to her over the next few days and weeks?
- 25 A. Okay, **so with that injury**, we knew it was swollen and she was started on pain relief and **antibiotics immediately**, we didn't know exactly what would

### **RITZER's SPCA Medical Report Exerts**

**13.10.2017** Ritza was given a **synthetic opiate painkiller Temgesic 1.6ml SC on the Friday afternoon**

**Temgesic is a painkiller - SC = Subcutaneous** under the skin injection  
Why has there been such a delay when Ritza was deemed so urgent?  
Dr Beer said in her Evidence in Chief that "Ritza was started on pain relief and **ANTIBIOTICS IMMEDIATELY.**"

**This was not correct.** A major contradiction  
According to Ritza's SPCA Medical Records, as stated by Dr Beer,  
**ANTIBIOTICS (Clavulox) was only started on the 16th October 2017.**

About 17,800 results (0.44 seconds)

### **Temgesic for dogs**

Buprenorphine (brand names: Buprenex®, Simbadol®, Belbuca®, Vetergesic®, Buprenodale®, Sublocade®, Suboxone®, Subutex®, Temgesic®) is **an opioid analgesic used to treat pain, or is used as a preanesthetic in the hospital or clinic setting.**

**Jess Beer** **Start Metacam tomorrow morning 2.5mg Sid =** veterinary abbreviation **meaning** to give medication once a day **a painkilling anti inflammatory** **NO ANTIBIOTICS.**

**13.10.2017** K Plowright's video 20171013\_131018.mp4, taken in the Hay Barn of Ritza being escorted out into an open area by Rhys Heatley.



**ALL SPCA photos & Body Worn Camera footage supplied by L Davis & K Plowright confirm Ritza's coat was in good condition, not matted, not contaminated when she was seized on 13.10.2017.**

This statement is not correct on the 13.10.2017 when Ritza was seized

**13.10.2017** NO matts behind the ears as stated in Ritza's SPCA medical records on **17.10.2017** by Groomer Katie Wright who was present in the raid on 13.10.2017

**13.10.2017** NO matted fecal/dirt contamination as stated on

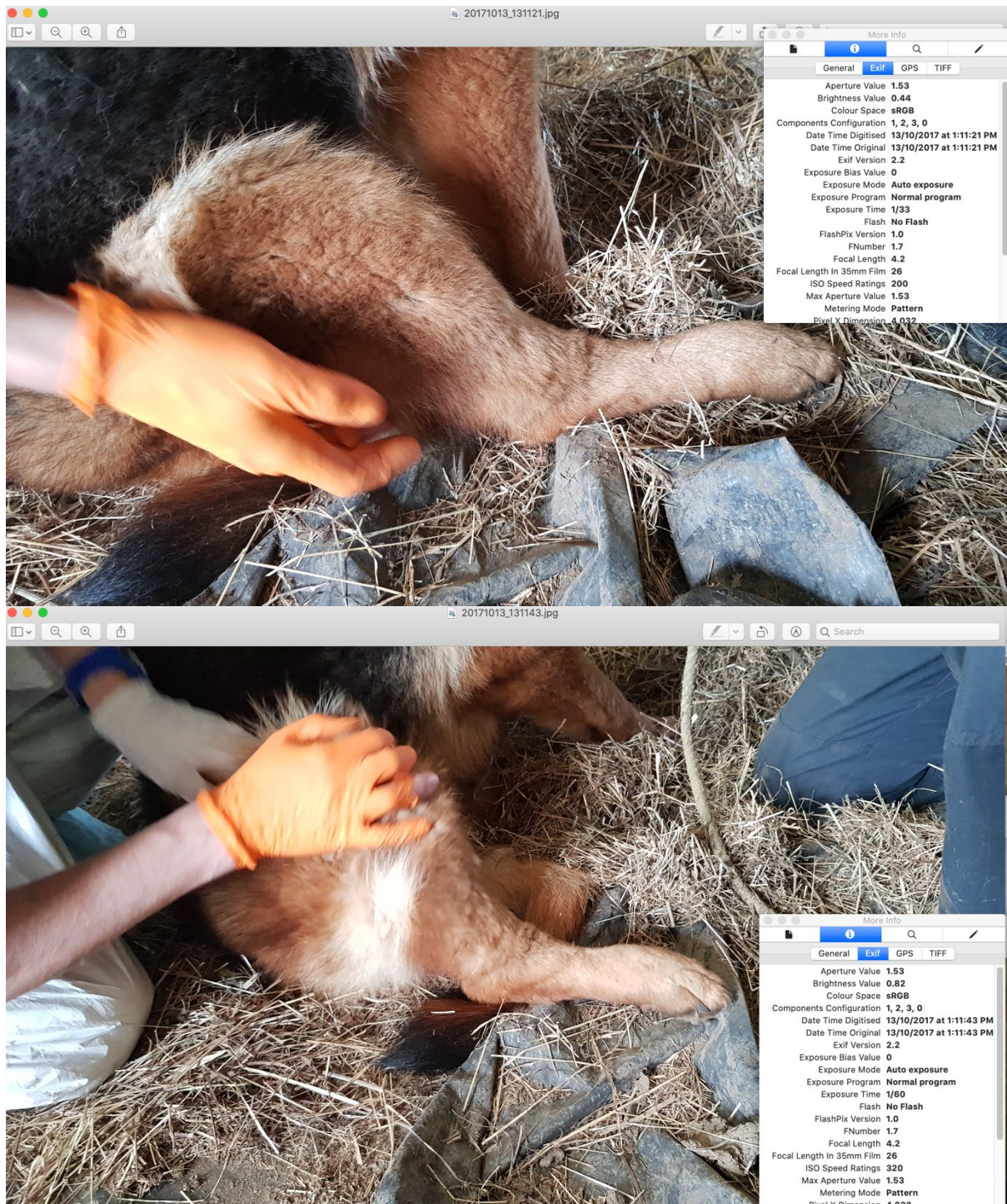**16.10.2017 by Vet: J Beer** Coat is matted and fecal/dirt contaminated. **Coat in better condition**

**13.10.2017** NB Ritza is walking on both hind legs - weight bearing at **13:10:01 on 13.10.2017**



**13.10.2017 photos taken from K Plowright's video in the Haybarn show clearly Ritza had no matts. No matts were identified by Dr Jess Beer 16.10.2017 of sternal thorax.**





**16.10.2017 RITZA's first full Veterinary Health check was not until MONDAY afternoon 16th October 2017.**

Vet: J Beer Coat is matted and fecal/dirt contaminated. Coat in better condition  
 Jess Beer Musculoskeletal - Discomfort on hind limb extension but compromised by right hind oedematous hock from ligature. Malodorous and 5 x 10 cm necrotic skin patch on medial aspect of hock. Temperament: friendly

Continue on Metacam to go on Clavulox (Antibiotics) 250mg give 1.5 tablets 2x daily. Use cone to stop licking.

**NO ANTIBIOTICS UNTIL 4 DAYS LATER = 96 hours, RITZA IS  
DIAGNOSED WITH GANGRENE**

I believe this has been a contributing factor in the demise of Ritzer. If you further view the Body Worn Camera footage I believe that it would be near impossible for a dog to get their hind leg wrapped around in their neck collar as seen on their footage. J Beer further describes Ritzer as having urinary and faecal staining as per their own Body Worn Camera footage and their numerous photos show that she was clean on the 13.10.2017 and not far from her was firm fresh faecal matter.

Therefore having viewed their evidence we strongly dispute it.

<https://dogdiscoveries.com/uncategorized/dogs-get-gangrene>

**At the Vet's Office**

How is gangrene diagnosed in dogs? The diagnosis includes several steps and procedures: a physical examination, blood tests – to check the white blood cells count (should be high in case of a gangrene), tissue culture – to determine the type of bacteria causing the infection and tissue samples examination – to find cellular evidence of cell death.

Preventing further infection spread – achieved with antibiotics.

Eliminating the infection – also achieved with antibiotics.

Treating the underlying cause that led to gangrene.

The prognosis for a dog with gangrene depends on several factors:

Location of the gangrene

Severity

How fast diagnosis was set

How fast treatment was initiated.

Sadly, when dogs get gangrene, it is much harder to spot than it is in humans. This is because the fur can cover the damaged tissues for a long period of time. When the fur falls off and the gangrene becomes visible, the condition has already significantly advanced.

What causes gangrene in dogs? When it comes to living organisms, blood is multi-functional. It carries and transports oxygen, nutrients and disease-fighting antibodies to every cell in the body. If the blood flow is impaired, cells die, infections develop and tissues are damaged beyond repair.

A gangrene case may start with an untreated open wound. The wound allows infiltration of bacteria and becomes infected. Untreated infections lead to gangrene. So generally speaking, gangrene occurs in cases of **impaired blood flow** and in cases of **wound infections**.

**A necrotizing infection causes patches of tissue to die.**

These infections are the result of bacteria invading the skin or the tissues under the skin. If untreated, they can cause death in a matter of hours. Fortunately, such infections are very rare. How long does it take for necrosis to occur?

Necrosis occurred in 2 of 4 cases in which the patient had been operated on within 3 hours of the injury, and our exploratory survival analysis estimates that 37% (95% confidence interval, 13%-51%) of all cases of ACS may develop muscle necrosis **within 3 hours of the injury**

[https://en.wikipedia.org/wiki/Necrotizing\\_fasciitis](https://en.wikipedia.org/wiki/Necrotizing_fasciitis)



**Necrotizing fasciitis (NF)**, also known as **flesh-eating disease**, is a bacterial **infection** that results in the **death** of parts of the body's **soft tissue**.<sup>[3]</sup> It is a severe disease of sudden onset that spreads rapidly.<sup>[3]</sup> Symptoms usually include red or purple skin in the affected area, severe pain, **fever**, and vomiting.<sup>[3]</sup> The most commonly affected areas are the **limbs** and **perineum**.<sup>[2]</sup>

Typically, the infection enters the body through a break in the skin such as a cut or **burn**.<sup>[3]</sup> Risk factors include **poor immune function** such as from **diabetes** or **cancer**, **obesity**, **alcoholism**, **intravenous drug use**, and **peripheral artery disease**.<sup>[2][3]</sup> It does not typically spread between people.<sup>[3]</sup> The disease is classified into four types, depending on the infecting organism.<sup>[4]</sup> Between 55 and 80% of cases involve more than one type of **bacteria**.<sup>[4]</sup> **Methicillin-resistant *Staphylococcus aureus*** (MRSA) is involved in up to a third of cases.<sup>[4]</sup> **Medical imaging** is often helpful to confirm the diagnosis.<sup>[4]</sup>

Necrotizing fasciitis may be prevented with proper **wound care** and **handwashing**.<sup>[3]</sup> It is usually treated with **surgery to remove the infected tissue**, and intravenous **antibiotics**.<sup>[2][3]</sup> Often, a combination of antibiotics is used, such as **penicillin G**, **clindamycin**, **vancomycin**, and **gentamicin**.<sup>[2]</sup> Delays in surgery are associated with a much higher risk of death.<sup>[4]</sup> Despite high-quality treatment, the risk of death is between 25 and 35%.<sup>[2]</sup>

Within 4 days in the SPCA environment our loving "Retza" has caught the highly contagious strep disease and the Vets and people supposedly caring for her neglected her, she was not treated

**17.10.2017** Coat in pretty good condition, does have some mild matting behind ears - NOT POSSIBLE SHE IS NOT A LONG COAT - Video demonstrates this is not the case screened on TV and the above photo taken at the scene on 13.10.2017

Ritzer **WAS NOT** Veterinary health checked

**18.10.2017** Rechecked leg. Still necrotic and malodorous. OK to continue with **Metacam** and **Clavulox**. Recheck again on Tuesday as may need a General Anaesthetic and debriding. Vet: D Dreyer

**WHY WAS RITZER NOT TREATED OR CHECKED IN THE LAST 6 DAYS = at least 144 hours??? From 18.10.- 24.10.2017 RITZER WAS NOT TREATED, not medically checked or bandage changed and/or wound dressing changed, no evidence of monitoring from 13.10.2017 - 27.10.2017 - Negligence Where is Body Camera Footage, Kenneling footage, Photos, the SPCA employees**

**statements and notes over the whole period of time.**  
**In the 11 days after being seized on the 13.10.2017 Ritza received**  
**Veterinary treatment ONLY 3 times namely**  
**16.10.2017 – 1<sup>st</sup> Full veterinary examination by Dr Beer**  
**18.10.2017 – 2<sup>nd</sup> veterinary treatment by Doug Dreyer**  
**24.10.2017 – 3<sup>rd</sup> veterinary treatment by Dr Beer**

**24.10.2017 Body Worn Camera K Plowright**  
**E3499\_E3498\_BCU\_A1047\_2017-10-23\_231743000\_-**  
**471933794.MOV**

12:38:28 J Wallace “How are they?”

12:38:30 K Plowright “Good”. Now I need to talk to you about one of them. One of the dogs that was removed from the barn. He had the lead wrapped around his leg.

12:38:35 Ritza? She would have panicked hearing all of that. Yes.

12:38:40 K Plowright the leg was enlarged as it came out.

12:38:45 J Wallace yes but there was no abrasions or anything like that.

12:38:49 L Davis No there was.

**12:38:50 K Plowright Yeah so long story short. There was a gangrenous infection. In there they are on a hardcore series of antibiotics now to try and get rid of that. But of course, if the gangrene can't be got on top of. We will get a vet having look further from there. But it had done quite a bit of damage that lead.**

12:39:18 L Davis “It was, so the lead was wrapped around from the cage, it was wrapped around that part of the leg.

12:39:24 K Plowright “so you got this part in through here on this little fella, just on in through here”

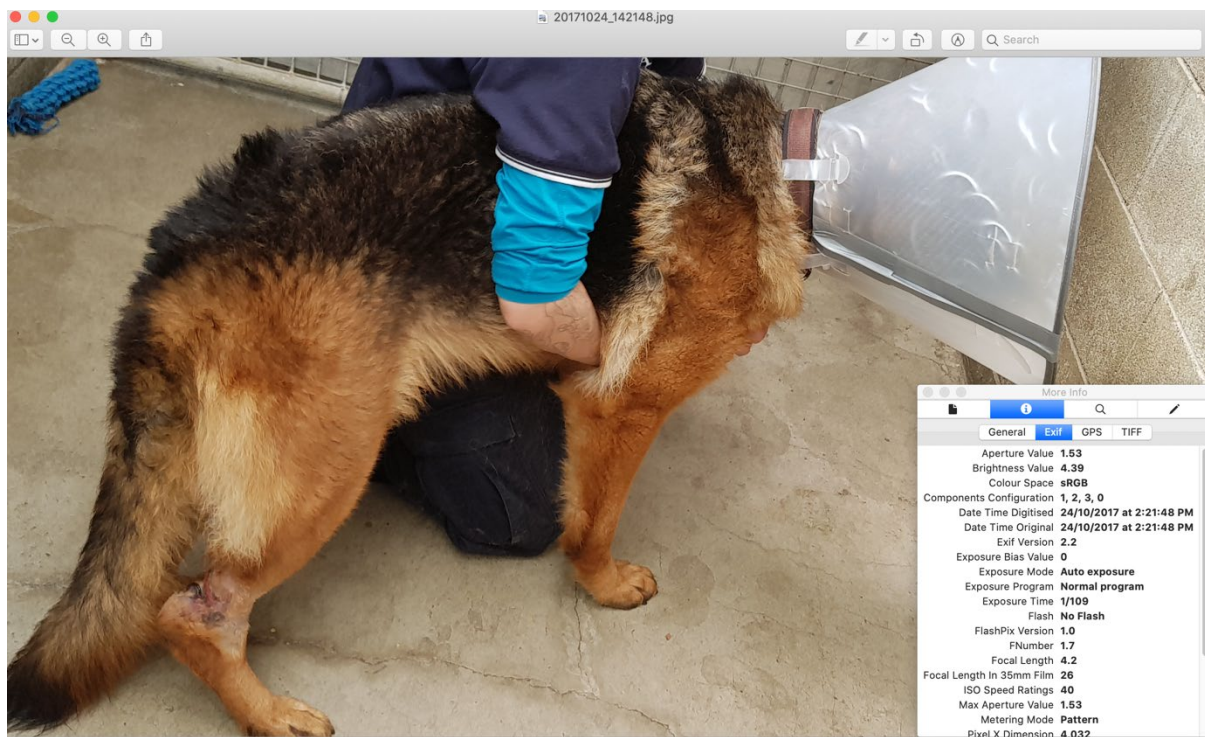
12:39:31 L Davis “And you can see the indent from the lead where it was. When we released her, she could not even put her leg – we have got it all on video – it was all stuck out the back like that. She couldn't put any weight on it. It was twice the size of her other leg. Still I haven't seen her today but last week it was still quite swollen and she was still quite lame in that leg. But they are doing everything they can to just try and combat that and just monitor her for the minute. We just wanted to let you know that she is of concern.

12:40:01 K Plowright "So they are bringing the dogs that were underweight up to normal weight, the matting and grooming is being done to get them to a healthier standard in the coat, so everything. When something is seized the SPCA is fully responsible for the health and wellbeing of those animals and that is what we are doing. So yeah however you will be responsible for all the veterinary all costs associated with that."

12:40:30 L Davis "Unless you surrender any, and then we will take the costs for that."

12:40:35 K Plowright "Have a think on that."

24.10.2017 Photo from K Plowright at SPCA 20171024\_142148.jpg



24.10.2017 Vet: J Beer rechecked leg. RHS lesion around hock, full thickness open purulent wound with granulation tissues but deep to Achilles tendon. Weight bearing and surprisingly comfortable with it.

24.10.2017 Kevin Plowright gives permission for this animal to go under anaesthesia for the purpose of a hip dysplasia test and ear exam and any other exam/treatment deemed necessary to mitigate possible suffering while the animal is in our care.



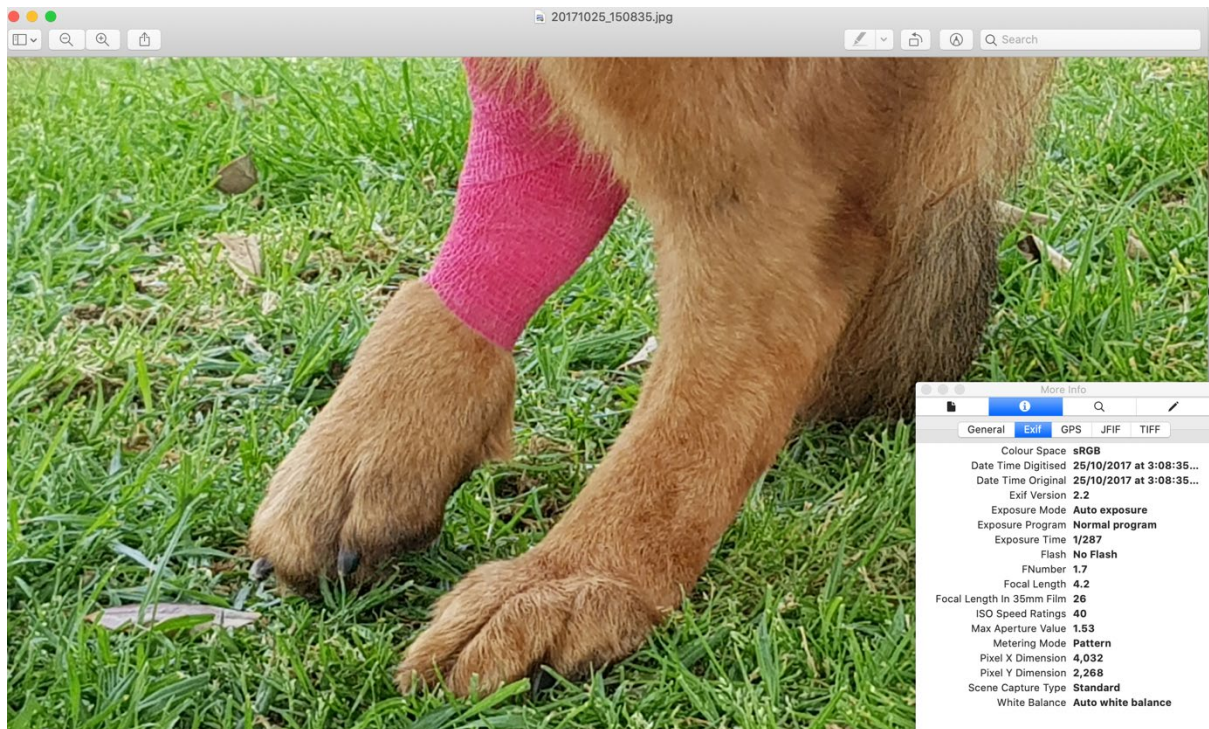


Photo from K Plowright collection 20171025\_150835.jpg of Ritza on 25.10.2017 at 3.08 pm, it appears that this bandage is too tight, her foot is swollen.

**25.10.2017**      **General Anaesthetic X-ray hips v/d Jess to assess.**  
Clip fur around wound and scrub with hypercleanse. Excise necrotic skin, wound granulating, but achilles tendon exposed with part of the tendon necrotic. Pack wound with manuka honey, bandage. Continue with antibiotics and metacam.


**25.10.2017**      Slightly matted fur clipped from sternal thorax. **WHY?**



**25.10.2017 This photo of Ritza above is taken by K Plowright NB: Both front legs, shaved and injection sites, sternum thorax shaved but it is not the same as the front legs. Is this photo taken after or before Ritza had been given General Anaesthetic X-ray hips v/d Jess to assess.**



20171013\_131018.mp4







13.10.2017 2x Screen Shots taken from K Plowright's video of Ritza at 13:10:15 20171013\_131018.mp4 with Rhys Heatley

**26.10.2017** **ALARM BELLS...**Discussion with KP/LD, vets, sort out team, canine attendants required tomorrow morning regarding further management of this case.

*AA noted non weight bearing on RH and foot appears swollen. Required muzzle for examination due to high pain level associated with wound RH.*

*Tarsus completely dropped (almost touching floor) on right side. All digits held in slightly flexed position. Bandage has significant strike through.*

*0.4mg/kg methadone administered IM to facilitate bandage change.*

*Assessment: Clinical signs of 'dropped tarsus' with digits in flexed position is consistent with gastrocnemius tendon injury (likely rupture) and intact SDFT dog is very painful. **INFECTION - Lack of hygiene in SPCA care***

***With an injury to the achilles tendon as well as infection, further treatment would require infection control, tendon repair (if possible) and long term post-operative care and physiotherapy. Surgical treatment typically requires specialist input.***

***Due to severe level of pain, level and complexity of injury, long term postoperative care, need for frequent bandage changes and sedation, dogs' level of distress with cage confinement and wearing E-COLLAR, human euthanasia is recommended.***

[353] Judge Grau This charge is proved. If this dog had not been left tethered as it was for an extended period of time, she would not have got tangled in her lead, ultimately with fatal consequences. Four of the SPCA's witnesses expressed the opinion that this injury was not caused in a matter of minutes."

**Evidence:** Body Worn Camera L Davis 13 October 2017 at 12:48:08 Rhys Heatley "There are two dogs beside the shed, Jo said there are more in the shed." L Davis "Cool da da da Kevin"

Although a very rare occurrence, canine gangrene is **similar to the condition found in humans**. Among the common shared symptoms are: Swelling of the area caused by infection. Foul-smelling discharge caused by dying tissues.<sup>12/07/2017</sup>

What is gangrene caused by?

**An untreated bacterial infection** can cause gangrene.

Traumatic injury. Gunshot wounds or crushing injuries from car crashes can cause open wounds that let bacteria into the body. If the bacteria infect tissues and remain untreated, gangrene can occur.<sup>11/02/2021</sup>

Can you heal gangrene?

The prognosis is generally favorable except in people in whom the infection has spread through the bloodstream. **Gangrene is usually curable in the early stages with intravenous antibiotic treatment and debridement.** Without treatment, gangrene may lead to a fatal infection.

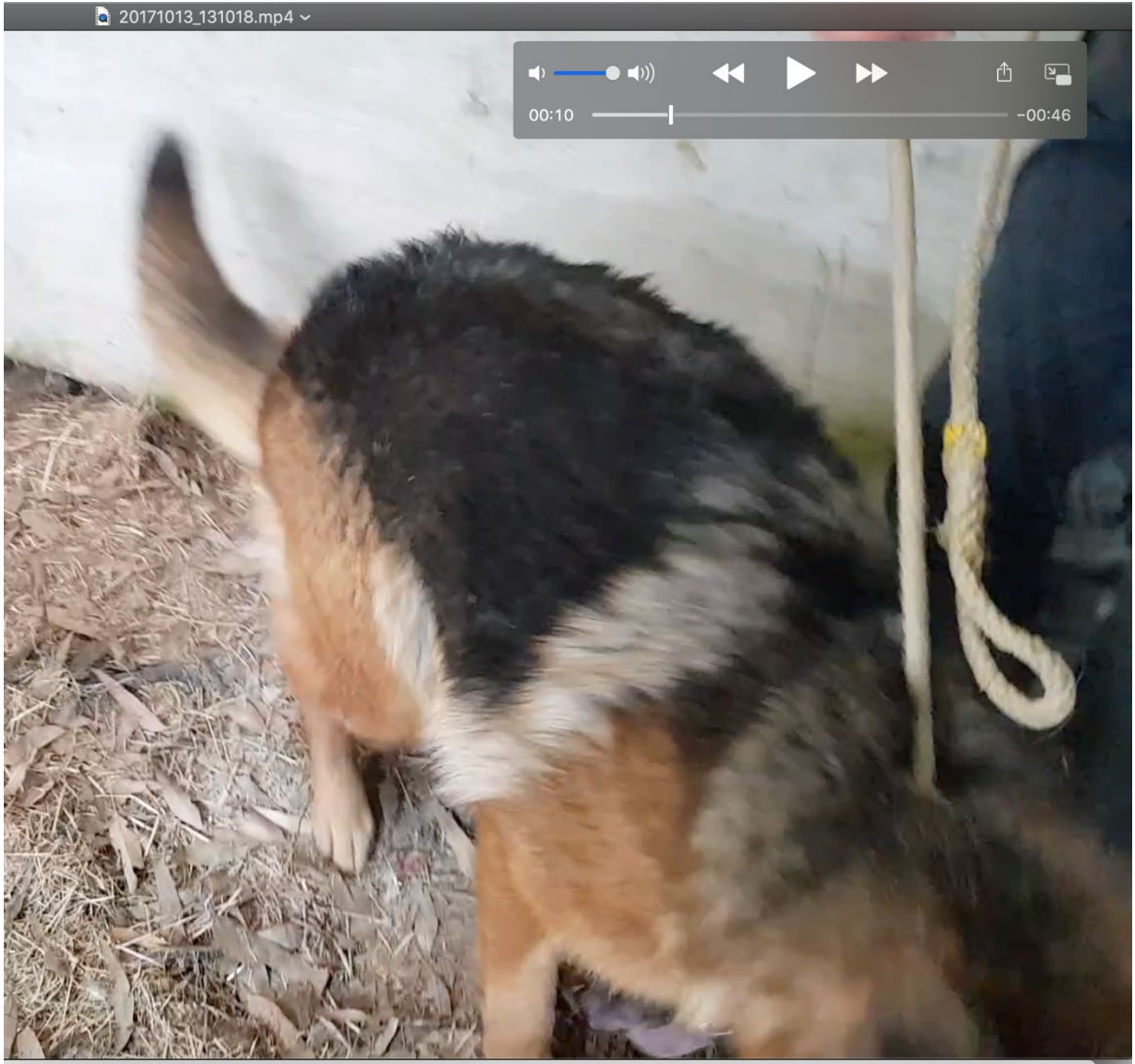



The requirement for a two-metre tether is not the minimum standard or even recommended best practise under the Code. It appears to be an arbitrary instruction from the SPCA

There appears to be no obvious swelling as described by Ms Davis Statement "Her leg was double the size we took a video of it" Body Worn Camera Footage K Plowright 24.10.2017


Photos = Screen shots from K Plowright's 1 minute video as Ritza is walked out by Rhys Heatley.



1. Haybarn Ritza K Plowright's video 13 Oct 2017 10 seconds after release weight bearing NB Right hand Back Leg Toes clearly defined
2. Haybarn Ritza K Plowright's video 13 Oct 2017 17 seconds after release standing, stepping out, weight bearing NB Right hand Back Leg Toes clearly defined
3. Haybarn Ritza K Plowright's video 13 Oct 2017 17 seconds after release stepping out weight bearing NB Right hand Back Leg Toes clearly defined. Look at her front leg she is stepping out moving forward while being restrained by Rhys Heatley NB both hind legs are firmly on the ground moving forward
4. Haybarn Ritza K Plowright's video 13 Oct 2017 23 seconds after release standing, weight bearing NB Right hand Back Leg Toes clearly defined
5. Haybarn Ritza K Plowright's video 13 Oct 2017 24 seconds after release standing about to sit down weight bearing NB Right hand Back Leg Toes clearly defined
6. Haybarn Ritza K Plowright's video 13 Oct 2017 25 seconds after release stepping out weight bearing NB Right hand Back Leg Toes clearly defined
7. Haybarn Ritza K Plowright's video 13 Oct 2017 33 seconds after release standing, weight bearing with Rhys Heatley NB Right hand Back Leg Toes clearly defined











[124] Judge Grau      **“Dr Beer said you could not see the definition of the dog’s toes in a photograph because the entire foot was swollen.”**

[125] Judge Grau      **“The dog could not or would not put its leg on the ground after release.”**



[126] Judge Grau      **PAGE 28 “Dr Beer’ considered the rope would have been around Ritza’s leg for hours, not just a few minutes. In Dr Flint’s view the rope was around the leg which means it had **been moving around in the area to make that happen and the wound was not a fresh wound.”****



Photo 13.10.2017 taken by K Plowright in the Haybarn at the alleged scene. NOTE:

1. There was NO ROPE wrapped around Ritza’s leg.
2. The photos – screen shots taken from the 1 minute video by K Plowright **PROVE Ritza was weight bearing**, using her hind leg to move forward, using her toes definitively immediately after release.
3. The area in which Ritza was found was NOT all worked up, as stated by Dr Flint from moving around if she had somehow created this situation herself. The area was pristine, the hay was still in place. Comparing with the Pirelli you can see how he has got worked up and the floor is bare.
3. **There is no wound therefore** Dr Flint’s statement is incorrect and misleading the Judge and court and public under oath. The above photos and Body Camera footage / Video footage taken by both Inspectors prove the skin was not broken, no abrasion, no cut,



no bruising, no wound, on the 13.10.2017 at 1:21 pm before departing from the farm.

### Transcript Page 42 of 93 [193]

In cross examination Dr Dreyer was referred to German Shepherd breed standard weights, **with which he was unfamiliar**. He said that, in using the Purina scale, you do not take the breed of the dog into consideration. It was used as a body scoring condition for all breeds.

Reserved Decision Judge Blackie 5 December 2019 Page 14 of 21 Par 46

“Dr Dreyer said that he had considerable experience with German Shepherd dogs, he had been the veterinarian to the German Shepherd Club in South Africa.”

20191206114229294.pdf (page 14 of 21)

Q dreyer

[46] Both Mr Plowright and Dr Dreyer were cross-examined by the respondents. Mr Plowright rejected the contention that the tree canopy would have been adequate shelter against the weather. He also rejected the suggestion that the dogs were not dehydrated and that they were fit and well-muscled. Dr Dreyer said that he had considerable experience with German Shepherd dogs, he had been the veterinarian to the German Shepherd Club in South Africa. The fleas could have been detected much earlier. The matt and her fleas were responsible for the dermatitis.

----- Forwarded message -----

From: **Sonia van Kraayenburg** <[sonia@grehenheim.co.za](mailto:sonia@grehenheim.co.za)>  
Date: Wed, Dec 11, 2019 at 9:35 PM  
Subject: RE: German Shepherd Federation of South Africa  
To: Barbara Glover <[volkerson88@gmail.com](mailto:volkerson88@gmail.com)>

Good Morning Barbara

We have **never** heard of such a person. The GSD Federation does not employ vets, but of course works closely with many of them

Regards

Sonia van Kraayenburg

061 495-5077

083 302-0536

**Arabis Road, Kameeldrift West, Pretoria**

061 494 4208 ■ 061 495 5077 Postnet Suite 431, Private Bag X0001, Ifafi 0260

[info@petapartments.co.za](mailto:info@petapartments.co.za)

S 25° 42' 14" - E 27° 57' 49"

CAUTION: The information contained in this e-mail is confidential and may be legally privileged. If the reader of this message is not the intended recipient, you are hereby notified that any use, dissemination, distribution or reproduction of this message is prohibited.

**From:** Barbara Glover [mailto:[volkerson88@gmail.com](mailto:volkerson88@gmail.com)]

**Sent:** Sunday, December 8, 2019 02:53

**To:** [sonia@grehenheim.co.za](mailto:sonia@grehenheim.co.za)

**Subject:** German Shepherd Federation of South Africa

Good Afternoon Frikkie,

I am sorry we do not have your email address and we are hoping this email address works.

We would really appreciate if you could confirm receipt of this email and even more so if you can help us with some information.

Frikkie did your GSD Club have a Vet called Doug Dreyer employed by the German Shepherd Federation of South Africa? If so could you please tell me when and for how long and was he any good? Did you have any complaints? He did not call it the German Shepherd Federation of South Africa, he named it the German Shepherd Club of South Africa and there is no such club according to our research. He has been very evasive and does not have a clue about German Shepherds, this is why we thought we would contact you. No - one knows German Shepherds and South Africa better than you.

We look forward to hearing from you. We hope this email finds you all well and looking forward to the Christmas spirit.

Kind regards

Barbara Glover

**Affidavit K Plowright sworn and signed 18 January 2018 Page 16 of 18 Paragraphs 78 – 81 regarding Ritza's euthanasia.**

**Important Note:-**

**Par. 78 => the infection have become gangrenous**

**Par. 80 "Ritza was inspected by their own veterinarian."**

**This sworn statement is PERJURY!**

**Inspector Plowright instructed Dr Jess Beer NOT to email through Ritza's medical records and photos which they had discussed early morning on the 27<sup>th</sup> October 2017.**

**Not supplying veterinary medical records which is absolutely against the Veterinary Code of Ethics to the Vet requested to give a second opinion (this was not forthcoming at all and only received on the 3rd April 2018 = 5.5 months later)**

**Kevin Plowright confirmed this at the "Interview" in November 2017 at Auckland SPCA, Mangere.**

Dr Mark Clinning was not even supplied with medical records and photos. He was simply told by Jess Beer her opinion.

**The law states we are entitled to an independent second veterinary opinion as does the Veterinary Code of Ethics complete with all medical records.**

**These records were received with partial discovery 03.04.2018 = 5 months later after repeated written requests from our lawyer.**

At the meeting on the 9th November 2017 at the SPCA with Ray Sheath an ex Policeman with 22 years in the Police Force representing my mother, L.Davis / K.Plowright, when questioned why were Retza's medical records not emailed through to Dr Mark Clinning,

**K.Plowright said he had told Jess Beer NOT to send them through! He also told Ray Sheath not to speak, he cannot ask any questions although he was representing my mother. R. Sheath has videoed the whole meeting for evidence.**

**Dr Mark Clinning of Takanini Veterinary Associates DID NOT INSPECT RITZA, this was a breach of s 138 and Perjury.**



78. Ritza had further complications due to her leg having been without blood flow for a prolonged period. An area of skin and tendon and other tissue of her hock was dying and the infection have become gangrenous.
79. We considered whether amputation of the leg was an option but due to Ritza being a large dog breed this was not practicable. SPCA veterinarian Jess Beer recommended euthanasia.
80. Pursuant to section 138 of the Animal Welfare Act, we invited Ms Wallace Ms Glover to have the opportunity of seeking a second veterinary opinion. They accepted this and Ritza was inspected by their own veterinarian. Their veterinarian recommended euthanasia or amputation. Ms Wallace and Ms Glover agreed to Ritza being euthanized.
81. Ritza was euthanized on Friday, 27 October 2017.

**We now question whether this in fact was our dog because at NO STAGE was she identified by microchip. Our Vet Dr Mark Clinning from Takanini Veterinary Associates was denied access by Kevin Plowright – what did Kevin Plowright have to hide.**

**RETZA WAS NOT INSPECTED BY OUR VETERINARIAN AT ANY TIME WHILST IN SPCA CARE AS SWORN BY KEVIN PLOWRIGHT's IN HIS AFFIDAVIT 15.01.2018**

## It is to be noted Gribbles did not identify Ritza by microchip before doing the autopsy.

LABORATORY Gribbles Veterinary Pathology Ltd- Auckland

LABADDR1 37-41 Carbine Road

LABADDR2 Mt Wellington

REPORTFEE 347.19

@RESULTS

291916 RITZA NEC nr -

@COMMENTS

AU17-36008

Patient/Animal Identification: Ritza #291916 Dog #15.

Necropsy duration: 70 minutes.

Gross Examination: An adult female entire black and tan German Shepherd dog was submitted for post mortem examination by Inspector Kevin Plowright of the Auckland SPCA; this was conducted on 30/10/17. The dog weighed 31.3 kg and was in fair body condition (Body condition score 3/5, Purina Pet Care Centre scale, as reproduced in the Animal Welfare (Dogs) Code of Welfare 2010) with mild post mortem changes.

There was scant tartar on her teeth. The right fore dorsal antebrachium had been shaved and the ventral neck/thorax had an area of alopecia and lichenification. Red fluid oozed from the nostrils.

There was a skin and subcutis defect on the caudal aspect of the right hock proximal to the tarsocrural joint, with an irregularly shaped granulating wound and some yellow/green surface exudate; ruptured green/white ends of the common calcaneal tendon were identified. The lateral digital flexor tendon remained intact. The edges of the skin defect were red to grey/black. The area was oedematous and had been shaved.

The lungs, liver and mesentery were diffusely reddened.

There were green areas within two ileocecal lymph nodes.

The stomach contained dog biscuits. The heart weighed 248 g, and the liver weighed 1447 g. No other gross abnormalities were identified. Photographs were taken during the necropsy. Samples of a range of organs were collected for histopathology, if requested. A sample of fresh ileocecal lymph node was also frozen for further testing, if requested.

Gross diagnosis:

Ventral neck/thorax dermatitis.

Right hock skin and soft tissue wound with common calcaneal (Achilles) tendon rupture.

Probable visceral congestion.

Ileocecal lymph node pigmentation.

Comment: Jess and Kevin, the main finding at post mortem in this dog was the right hock wound that you were managing at the SPCA. I can confirm that the "Achilles" tendon was ruptured and that there was an associated wound. This was consistent with a traumatic foot injury, and consistent with your supplied history of a ligature injury. The presence of granulation tissue is consistent with a wound days to weeks old, consistent with the supplied history. It is my opinion that this injury would have caused severe pain, suffering and distress. An injury of this nature should be treated immediately to alleviate pain and distress (e.g. with pain-killing medications, bandaging and other measures such as amputation) in accordance with Section 11 of the Animal Welfare Act 1999, and Minimum Standard (10) - Ill Health and Injury, of the Animal Welfare (Dogs) Code of Welfare 2010.

The other post mortem findings in this dog were likely of trivial importance. It could be this dog had a flea allergy dermatitis leading to the ventral neck/thorax alopecia. The congestion of viscera (especially the pulmonary congestion) was probably related to barbiturate euthanasia and post mortem hypostatic congestion. The lymph nodes could have appeared green due to pigment deposition, although another cause (e.g. lymphadenitis) cannot be completely ruled out without culture and histopathology of the node.

Please note that the remains of this case will be routinely disposed of in two weeks' time, unless other arrangements for their storage or disposal are requested.

Michael Hardcastle, BVSc, MVStds (Hons), Diplomate ACVP Registered Specialist in Veterinary Anatomical Pathology Tel: 09 5744 708 | Email: michael.hardcastle@gribbles.co.nz

NECROPSY performed and reported by Gribbles Veterinary, Carbine Rd, Auckland Reference Ranges and Method Reference will be supplied on request Testing Requested

1 x Necropsy

1 x Necropsy

1 x Necropsy

@END

IMPORTANT - GRIBBLES is a division of Healthscope Limited.

This email contains confidential information intended only for the person named above and may be subject to legal privilege. If you are not the intended recipient, any disclosure, copying or use of this information is prohibited.

Healthscope provides no guarantee that this communication is free of virus or that it has not been intercepted or interfered with. If you have received this email in error or have any other concerns regarding its transmission, please notify postmaster@gribbles.co.nz. You must destroy the original transmission and its contents. Any views expressed within this communication are those of the individual sender, except where the sender specifically states them to be the views of Healthscope.

If this document is not required for record keeping purposes please consider the environment before storing or printing. This communication should not be